

# CHAPTER 49 ■ FACELIFT

CHARLES H. THORNE

This chapter summarizes my personal approach to facelifting, as well as the most common techniques employed by other plastic surgeons.

---

## STATE OF THE ART

---

Facelifting was first performed in the early 1900s and for most of the 20th century involved skin undermining and skin excision. A revolution occurred in the 1970s when the public became exponentially more interested in the procedure and Skoog described dissection of the superficial fascia of the face in continuity with the platysma in the neck. Since then techniques have been described that involve every possible skin incision, plane of dissection, extent of tissue manipulation, type of instrumentation, and method of fixation. Many of these “innovations” provide little long-term benefit when compared to skin undermining, and expose the patient to more risk. The trends in facelifting at the present time are best summarized as follows:

1. *Volume versus tension*—Placing tension on the skin is an ineffective way of lifting the face and is responsible for the “facelifted” look and for unsightly scars and distortion of the facial landmarks such as the hairline and ear. The current trend is toward redistributing, or augmenting, facial volume, rather than flattening it with excessive tension.
2. *Less invasive*—That the more “invasive” techniques have not yielded benefits in proportion to their risk combined with the public demand for rapid recovery has led to simplified procedures.
3. *Facial harmony*—The goal is to help a patient look better, not weird or operated on. Excessive tension, radical defatting, exaggerated changes, and attention to one region while ignoring another may result in disharmony. The face is best analyzed and manipulated with the entire face (and the entire body) in mind, not the individual component parts, lest the “forest be lost for the trees.”
4. *Recognition of atrophy*—The process of aging involves not only sagging of the tissues and deterioration of the skin itself but atrophy of tissues, especially fat, in certain areas. Most patients are best served with limited defatting and may require addition of fat to areas of atrophy.

---

## BENEFITS AND LIMITATIONS OF FACELIFTING

---

Facelifting addresses only ptosis and atrophy of facial tissues. It does not address, and has no effect on, the quality of the facial skin itself. Consequently, facelifting is not a treatment for wrinkles, sun damage, creases, or irregular pigmentation. Fine wrinkles and irregular pigmentation are best treated with skin care and resurfacing procedures (see Chapters 13 and 44). Deep creases, such as the labiomentalar creases, may be im-

proved by facelifting. Other facial creases, however, will not be improved by facelifting (nasolabial creases), and even if improved somewhat, will still require additional treatment in the form of fillers or muscle-weakening agents (see Chapters 45 and 46).

The above disclaimer notwithstanding, the facelift is the single most important and beneficial treatment for most patients older than age 40 years who wish to maximally address facial-aging changes.

Patients have individual aging patterns determined by genetics, skeletal support, and environmental influences (Fig. 49.1). Some combination of the following, however, will occur in every patient (those characteristics improved by facelifting are in bold print):

1. Forehead and glabellar creases
2. Ptosis of the lateral eyebrow
3. Redundant upper eyelid skin
4. Hollowing of the upper orbit
5. Lower eyelid laxity and wrinkles
6. Lower eyelid bags
7. Deepening of the nasojugal groove and palpebral-malar groove
8. **Ptosis of the malar tissues**
9. **Generalized skin laxity**
10. Deepening of the nasolabial folds
11. Perioral wrinkles
12. Downturn of the oral commissures
13. **Deepening of the labiomentalar creases**
14. **Jowls**
15. **Loss of neck definition and excess fat in neck**
16. **Platysmal bands**

A minority of aging characteristics is improved by facelifting. Those that are addressed, however, are of fundamental importance to the attractive, youthful face. The facelift confers another benefit that is more difficult to define. Aging results in jowls and a rectangular lower face. A facelift lifts the jowls back into the face, augmenting the upper face and narrowing the lower face, producing the “inverted cone of youth.” **This change in overall facial shape from rectangular to heart-shaped is subtle but real, and is a benefit that no other treatment modality can provide.**

---

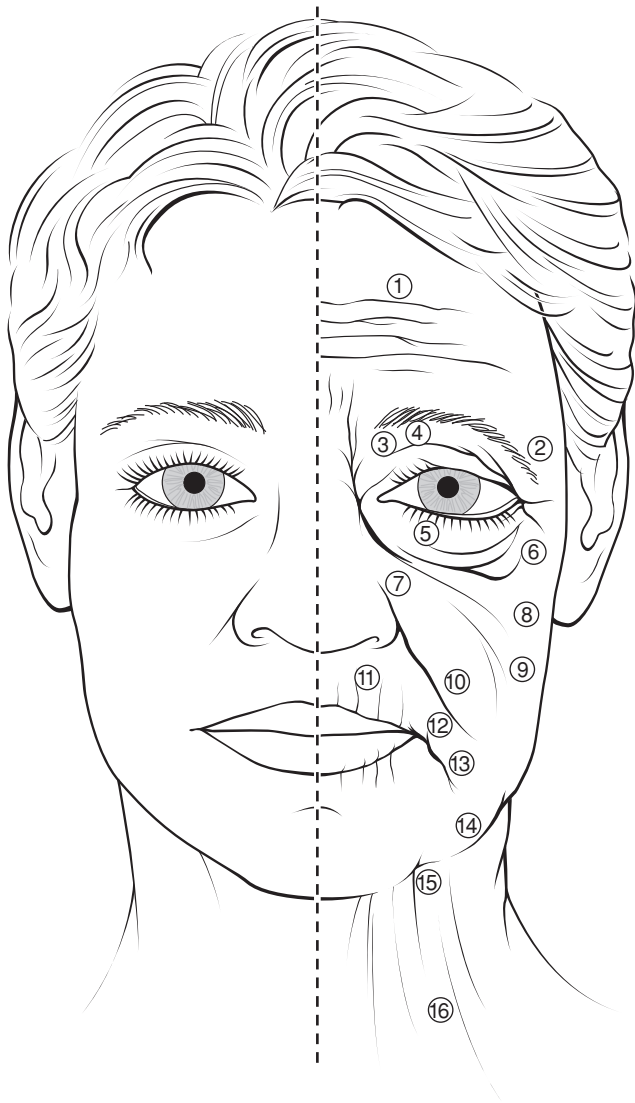
## PREOPERATIVE PREPARATION

---

### History

---

The same compulsive medical history that is indicated before any surgical procedure is obtained when evaluating a patient for aesthetic surgery of the face. Specific inquiry is made regarding medications, allergies, medical problems, previous surgery, and smoking and drinking habits. The most common complication of facelifting is a hematoma and therefore the history focuses on factors that predispose to postoperative bleeding,



**FIGURE 49.1.** Aging changes in the face. 1. Forehead and glabella creases. 2. Ptosis of the lateral brow. 3. Redundant upper eyelid skin. 4. Hollowing of the upper orbit. 5. Lower eyelid laxity and wrinkles. 6. Lower eyelid bags. 7. Deepening of the nasojugal groove. 8. Ptosis of the malar tissues. 9. Generalized skin laxity. 10. Deepening of nasolabial folds. 11. Perioral wrinkles. 12. Downturn of oral commissures. 13. Deepening of labiomental crease. 14. Jowls. 15. Loss of neck definition and excess fat in neck. 16. Platysmal bands.

specifically hypertension and medications that affect clotting. Surgery is not performed until the patient has been off of aspirin for 2 weeks. Facelifting is probably contraindicated in patients on warfarin (Coumadin) or clopidogrel (Plavix), even if they are allowed by their physicians to stop these medications. At the very least, facelifting on such patients is performed with extreme conservatism and only after every possible means of eliminating the effects of these medications has been pursued. **Hypertension is probably the single factor that most closely correlates with postoperative hematomas, thus blood pressure must be under strict control.**

### Cigarette Smoking

Smoking increases the risk of skin slough, the second most common complication after facelifting (1). Patients are encouraged

to quit smoking permanently. Cigarette smoking, with all its deleterious effects on health, and having a facelift to feel better about oneself, are fundamentally contradictory. At the very least, patients should cease smoking 2 weeks prior to surgery. It is important that smokers know that they will never become “nonsmokers;” that is, the effects of smoking never totally disappear, and are certainly not gone in 2 weeks.

Because aesthetic surgery is elective, whenever there is a question about a preoperative medical condition, the procedure is postponed until appropriate consultations are obtained and all issues settled.

### Preoperative Photographs

Photographs are essential for at least four reasons: (a) assistance in preoperative planning; (b) communication with patients preoperatively and postoperatively; (c) intraoperative decision making; and (d) medicolegal documentation.

### Psychological Considerations

One of the most difficult challenges for the plastic surgeon is deciding which patients are not candidates, on an emotional or psychological basis, for elective aesthetic surgery. Studies suggest that patients frequently harbor secret or unconscious motivations for undergoing the procedure. A patient may state that he/she wants to feel better about him- or herself when the real motivation is to recapture a straying mate (unlikely to succeed).

Patients who have difficulty delineating the anatomic alterations desired or in whom the degree of the deformity does not correlate with the degree of personal misfortune ascribed to that deformity, are not candidates for aesthetic surgery. The tough, 50-year-old lawyer who states that she does not like her jowls is a far better candidate than the seemingly docile patient who cannot articulate what bothers her and defers to “whatever you think doctor.” The surgeon will regret proceeding with an operation when his or her instincts indicate that the patient is an inappropriate candidate.

### Preoperative Counseling

At the time of the preoperative consultation the patient is given written information concerning the planned procedure that reinforces the verbal information provided.

In addition to describing to the patient the anticipated results of the procedure, it is necessary to point out the areas where little or no benefit is expected. As described above, the nasolabial folds that may be softened slightly by a facelift but will reappear when the swelling disappears. Ptotic submandibular glands preclude a totally clean appearance to the neck. Fine wrinkles around the mouth will require a resurfacing procedure.

### Preoperative Instructions

Patients are instructed to shower and wash their hair on the night before surgery. On the morning of surgery another shower and shampoo are desirable. At a minimum the face is thoroughly washed. Although patients are not allowed to eat anything after midnight, they are instructed to brush their teeth and rinse their mouths with mouthwash.

Given that the single most important step in avoiding a hematoma is control of the blood pressure, patients with any tendency to high blood pressure are given clonidine 0.1 mg by

mouth preoperatively. Some surgeons administer the drug routinely to all patients. Clonidine is long-acting, however, and may lead to hypotension in healthy patients. Consequently, I prefer to use it selectively.

---

## ANESTHESIA

---

The subjects of anesthesia and which technique is the safest are poorly understood by patients. A facelift can be safely performed under local anesthesia with sedation provided by the surgeon, or by intravenous sedation or general anesthesia provided by an anesthesiologist. If the surgeon is to perform the procedure without an anesthesiologist, the patient must be completely healthy. The patient is given diazepam (Valium) 10 mg by mouth 2 hours preoperatively and brought to the facility by an escort. Meperidine (Demerol) 75 mg and hydroxyzine pamoate (Vistaril) 75 mg are administered intramuscularly. Once the effect is demonstrable, the patient is moved to the operating room to initiate the procedure. Midazolam (Versed) is given intravenously in 1-mg increments until the patient is sufficiently sedated to tolerate the injections of local anesthetic solution. Additional midazolam (Versed) is given as needed throughout the procedure, also in 1-mg doses.

In most cases, however, facelifts are performed with the help of an anesthesiologist. If the procedure is to be longer than 3 hours because of ancillary procedures, or if the patient has medical problems, then an anesthesiologist is always present.

The anesthesiologist decides where on the spectrum from conscious sedation to general anesthesia the patient is best kept, and it may vary during a procedure. The patient may be under general anesthesia, by any definition, during the injection of the local anesthetic solution, and conscious during other phases of the procedure. In other patients, despite the efforts of the anesthesiologist to provide conscious sedation, the medication will result in loss of the airway, requiring that the anesthesiologist convert the procedure to general anesthesia.

Patients and some other physicians incorrectly believe that patients are safer with “twilight” anesthesia, whatever that is. Local anesthesia is safe and general anesthesia is usually safe, but the *least* safe anesthetic and the one requiring the most skill to administer is the “in between” anesthetic that patients call “twilight.” Patients who are sedated but who do not have an endotracheal tube in place to control the airway are more likely to have airway problems than a patient who is completely asleep with the ventilation controlled by the anesthesiologist. Many patients who undergo facelift procedures believe they are receiving “sedation,” but they are really receiving intravenous, general anesthesia without an endotracheal tube. There is nothing wrong with the technique in the hands of an expert, but patients should be disabused of the notion that it is safer than general anesthesia.

---

### Blood Pressure Control

---

An ideal anesthetic for facelifting would be associated with a constant blood pressure and no need for vasoactive medications to either raise or lower it. Dips in blood pressure treated with vasoconstrictors, or spikes in blood pressure treated with vasodilators, are to be avoided if at all possible. Blood pressure is ideally kept at approximately 100 mm Hg systolic, depending on the patient’s preoperative blood pressure. Excessive hypotension may obscure bleeding vessels that are best coagulated. Hypertension may be associated with excessive bleeding. The anesthesiologist should inform the surgeon of every medication administered, and the surgeon should inform the

anesthesiologist of any increased tendency for bleeding. There are no secrets in the operating room.

---

## Local Anesthetic Solution

---

Regardless of the type of sedation/anesthesia chosen, the face is injected with local anesthetic solution prior to the dissection. There is some controversy and little definitive data regarding the maximal amount of local anesthetic that can be used. The package insert in the lidocaine bottle states that no more than 7.5 mg/kg of lidocaine should be administered when given in combination with epinephrine. We know, however, that when dilute solutions are used in liposuction of the *body*, that more than 30 mg/kg of lidocaine is safe. There is evidence that the face differs from the body and that the high lidocaine doses used in the body are not safe in the face. It is reasonable to conclude that doses higher than the 7.5 mg/kg recommended by the manufacturer are *probably* safe in the face, but this is unproven. Until such proof exists, plastic surgeons should limit the total dose to approximately 7.5 mg/kg. In the my practice, I dilute 500 mg lidocaine (one 50 mL vial of 1% lidocaine, which is the approximate maximum dose for a 70-kg patient) to whatever volume is necessary to perform the entire procedure, no matter how dilute that solution is.

**The most common solution I use is 50 mL 1% lidocaine plus 1 mL epinephrine 1:1000 plus 250 mL normal saline for a final volume of 301 mL and a final solution concentration of 0.17% lidocaine with epinephrine 1:300,000.**

Because of the dilute nature of the solution used and the fact that the total dose of lidocaine does not exceed the manufacturer’s recommendation, I inject both sides of the face at the beginning of the procedure, despite recommendations by some that only one side should be injected at a time.

If the patient is adequately anesthetized, the injection of the anesthetic solution is rarely accompanied by *any* change in heart rate or blood pressure. The surgeon must constantly keep the injecting needle moving, however, to avoid a large intravascular injection of the epinephrine-containing solution. If a major change in blood pressure occurs, the surgeon and anesthesiologist must assume that an intravascular injection has occurred and act quickly to limit the extent of hypertension.

---

## FACELIFT ANATOMY

---

If either skin undermining alone or subperiosteal undermining alone is performed, the surgeon can, to some extent, ignore the anatomy. These two planes of dissection are safe. Manipulation of the tissues between these two planes, however, necessitates an understanding of and constant attention to the anatomy to avoid complications.

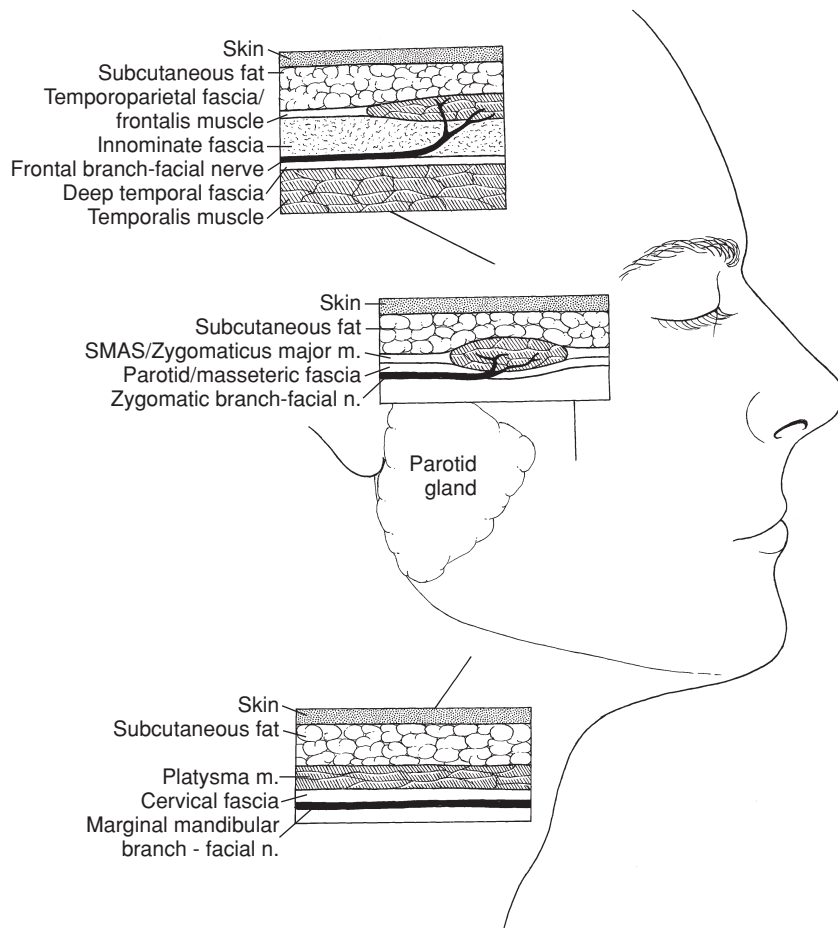
---

### Anatomic Layers

---

There are five layers of critical anatomy: skin; subcutaneous fat; the superficial musculoaponeurotic system (SMAS)—muscle layer; a thin layer of transparent fascia; and the branches of the facial nerve (Fig. 49.2). These five layers are present in all areas of the face, forehead, and neck, but they vary in quality and thickness, depending on the anatomic area.

The first two layers, the skin and subcutaneous fat, are self-explanatory. The third layer (SMAS) is the most heterogeneous (2). It is fibrous, muscular, or fatty, depending on the location in the face. The muscles of facial expression are part of the SMAS layer (e.g., frontalis, orbicularis oculi, zygomaticus major and minor, and platysma). In the temporal region, this layer is not



**FIGURE 49.2.** The anatomic layers of the face. Although the quality of the layers differs in various areas of the face, the arrangement of layers is identical. The facial nerve (cranial nerve [CN] VII) branches innervate their respective muscles via their deep surfaces.

muscular but is fascial in quality and is represented by the superficial temporal fascia (or temporoparietal) fascia.

The fourth layer consists of a layer of areolar tissue that is not impressive in thickness or strength, but is always present and is a key guide to the surgeon as to the location of the facial nerve branches. In the temporal area, this layer is known as the innominate or subgaleal fascia; in the cheek, it is the parotid-masseteric fascia; and in the neck, it is the superficial cervical fascia. Once under the SMAS, the facial nerve branches can be seen through this fourth layer. If the layer is kept intact, it serves as reinforcement to the surgeon that he or she is in the correct plane of dissection. If a nerve branch is encountered without this fascial covering, the surgeon must be aware that the dissection is too deep and nerve branches may have been transected. Just as it is convenient, but not totally accurate, to think of the galea-frontalis-temporoparietal fascia-SMAS-orbicularis oculi-platysma as a single layer, it is useful to think of the subgaleal fascia-innominate fascia-parotid/masseteric fascia-superficial cervical fascia as a single layer.

The fifth layer is the facial nerve, which is discussed in detail below.

---

### Facial Nerve

---

If the surgeon remembers that the facial nerve branches innervate the respective facial muscles via their deep surfaces, the safe planes of dissection become obvious. Dissection in the subcutaneous plane, superficial to the SMAS-muscle layer, is safely performed anywhere in the face, whether it is the temporal region, cheek, or neck. Dissection deep to the SMAS, superficial to the facial nerve branches, requires care.

There are three to five frontal (or temporal) branches of the facial nerve that cross the zygomatic arch and innervate the frontalis muscle, orbicularis oculi, and corrugator muscles via their deep surfaces (3). Because the layers of anatomy, although present, are compressed over the arch, these branches are vulnerable to injury in this region. Dissection in this region can either be performed superficial to the nerve branches in the subcutaneous plane, or deep to the branches on the surface of the temporalis muscle fascia (deep temporal fascia) (4).

The zygomatic branches innervate the orbicularis oculi and zygomaticus muscles. One must remember that although the facial nerve branches travel deep to the SMAS layer, at some point these branches turn superficially to innervate the overlying muscles. Any dissection in the sub-SMAS plane in the cheek, whether as part of a composite rhytidectomy or standard dissection of the SMAS as a separate layer, necessitates a change of surgical planes at the zygomaticus major muscle to avoid transection of the branch to this muscle. The dissection plane changes from sub-SMAS to subcutaneous by passing over the superficial surface of the zygomaticus major and thereby preserving its innervation.

The buccal branches lie on the masseter muscle and are easily visualized through the parotid-masseteric fascia. Some buccal branches merge with branches of zygomatic origin to innervate the procerus muscle and provide additional innervation of the corrugator muscle. Consequently, the corrugator muscle receives innervation from the frontal, zygomatic, and buccal branches.

Earlier publications indicated that the marginal mandibular branches were located above the inferior border of the mandible in many cases. More recent studies demonstrate that, in fact, these branches are always located caudal to the inferior

border of the mandible. The cervical branches innervate the platysma muscle.

Anatomic studies indicate that there are fewer crossover communications between the frontal branches and marginal mandibular branches, which helps to explain why injuries to these nerves are less likely to recover function in their respective muscles than injuries to the zygomatic or buccal branches.

---

### Retaining Ligaments

---

In at least two areas of the face the anatomic layers are condensed and less mobile with respect to each other. These “ligaments” are areas where the skin and underlying tissues are relatively fixed to the bone (5). The zygomatic ligament (previously known as the McGregor patch) is located in the cheek, anterior and superior to the parotid gland and posteroinferior to the malar eminence. The mandibular ligament is located along the jaw line, near the chin, and forms the anterior border of the jowl.

The retaining ligaments restrain the facial skin against gravitational changes at these points. The descent of tissues adjacent to these points form characteristic aging changes such as the jowl. In addition, some surgeons feel that the ligaments must be released in order to redrape tissues distal to these points.

---

### Platysma Muscle

---

Although the platysma muscle is a component of the previously discussed SMAS–muscle layer, it deserves special attention because of its clinical importance. The medial borders of the two muscles decussate to a variable degree in the midline of the neck, helping to explain the variability of aging patterns in the neck (6). The medial borders of the muscles tend to become redundant with age and contribute to the appearance of bands in the submental region.

---

### Malar Fat Pad

---

The malar fat pad is part of the subcutaneous layer of the face. It is superficial to the SMAS layer represented in this region by the zygomaticus muscles. The malar fat pad appears to descend with age, leaving a hollow infraorbital region behind it and creating larger nasolabial folds and deeper nasolabial creases. Each of the major facelift techniques include a method to mobilize the malar fat pad and restore volume to the upper part of the face and malar region. As is discussed below, the extended SMAS technique involves mobilizing the malar pad in continuity with the SMAS layer. Other techniques involve mobilizing and repositioning the malar pad independent from the SMAS dissection.

---

### Buccal Fat Pad

---

The buccal fat pad is deep to the buccal branches of the facial nerve, anterior to the masseter muscle, and superficial to the buccinator muscle. Access to the buccal fat pad is achieved by performing a sub-SMAS dissection in the cheek and spreading it between the buccal branches of the facial nerve or through the mouth, by a stab wound in the buccinator muscle. Despite occasional indications to remove the fat pad in patients with very full faces, removal of cheek fat tends to ultimately make the patient look older. As a general rule, rejuvenation of the face involves redistribution, not removal, of fat.

---

### Great Auricular Nerve

---

The facelift operation inevitably disrupts branches of sensory nerves to the skin. Normal sensibility always returns eventually but numbness may persist for months postoperatively. The only named sensory nerve that is important to preserve is the great auricular nerve. With the head turned toward the contralateral side, the great auricular nerve crosses the superficial surface of the sternocleidomastoid muscle 6 to 7 cm below the external auditory meatus (7). At this point it is 0.5 to 1 cm posterior to the external jugular vein. The vein and nerve are deep to the SMAS–platysma layer, except where the terminal branches of the nerve pass superficially to provide sensibility to the skin of the earlobe. Transection of the great auricular nerve will result in permanent numbness of the lower half of the ear and may result in a troublesome neuroma.

---

### Tear Trough

---

The tear trough or nasojugal groove is an oblique indentation running inferiorly and laterally from the medial canthus. This groove is a subject of much attention at the present time. Although it is probably better included in a discussion of eyelid surgery, it deepens with age and is a frequent complaint of patients interested in facial aesthetic surgery (see Chapter 48). In general, facelift procedures do not address the tear trough. Redraping of orbital fat or microfat grafting is usually required.

---

## FACELIFT TECHNIQUES AND ALTERNATIVES

---

The facelift procedure can be performed in the subcutaneous plane, the sub-SMAS (deep) plane, the subperiosteal plane, or a combination of the above. Each of the most commonly used techniques is described in the following sections.

---

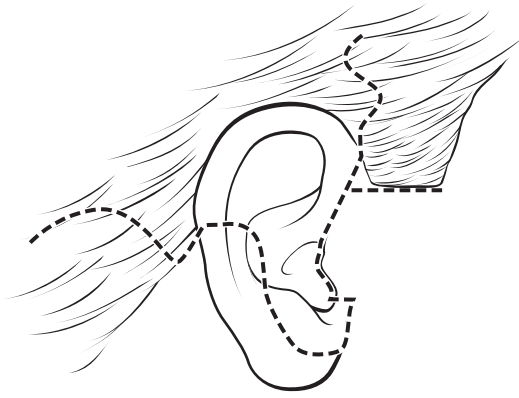
### Subcutaneous Facelift

---

The original facelift consisted of subcutaneous undermining only. The technique is still useful for an occasional patient, but more importantly, it is the basis for other techniques such as the SMAS technique, extended SMAS technique, and the SMASectomy–SMAS plication techniques.

Incisions are designed to avoid distortion of the hairline and ear and to maximally disguise the final scars (Fig. 49.3). The goal is a scar that is so inconspicuous that one has to look for it. Although this is not always the case given the variable and unpredictable nature of wound healing, it is always the goal. If the patient has never had surgery before and has a normal hairline and sideburn, the incision is initiated within the hair, just above the ear. In patients with previous facelifts, the sideburn may already be significantly raised and posteriorly displaced, and an incision within the hair will result in further distortion of the sideburn. These patients are candidates for an incision along the anterior hairline. Patients with thin, sparse hair may be candidates for the hairline incision, even if it is the first procedure they have ever had. A transverse incision is also designed just below the sideburn to allow additional excision of cheek skin without raising the sideburn any higher than desired by the surgeon.

The incision proceeds caudally along the junction of the ascending crus of the helix and the cheek. The eventual scar tends



**FIGURE 49.3.** Standard facelift incision. Regardless of the technique chosen, some form of this incision is employed. In the temporal region the incision is shown within the hair. In patients with extremely thin hair, previous facelifts or if performing the minimal access cranial suspension (MACS) lift, the incision is made along the anterior sideburn and temporal hairline, rather than as shown here. In this illustration, the incision is shown along the posterior margin of the tragus. In men, and in women with oily or hairy preauricular skin, an incision in the preauricular crease may be preferable. In the short scar technique, the incision is terminated at the bottom of the earlobe or just behind it, and the entire retroauricular portion of the incision is eliminated.

to migrate forward slightly and therefore should be placed 1 to 2 mm on the ear side of the ear–cheek junction. My preference is to make the incision in the same location in men. The incision is continued either at the posterior margin of the tragus (retrotragal) or in the pretragal region, usually in a natural skin crease. Patients, and many surgeons, erroneously believe that the incision along the posterior aspect of the tragus is always preferable. In fact, this incision frequently results in distortion of the tragus and is more likely a “tip-off” to a facelift than the preauricular incision. The novice surgeon is encouraged to perfect the pretragal incision prior to tackling retrotragal incisions.

When the retrotragal incision is made, the cheek skin is redraped over the tragus. The normal tragus is covered with thin, shiny, hairless skin (even in most men), and cheek skin is frequently not the ideal covering. I tend to use the retrotragal incisions in young women with thin, hairless cheek skin. In men, and in women with irregular pigmentation in the preauricular region, thick, oily cheek skin, or with furry cheeks, the incision is made in a preauricular crease. **The key to an invisible scar is absolute lack of tension, not its location.** If the retrotragal incision is chosen, the initial undermining is performed slowly and with care to avoid any damage to the tragal cartilage.

The incision passes beneath the earlobe and extends into the retroauricular sulcus. The incision is placed slightly up on the ear because it is also prone to migration and is best hidden if the final scar rests in the depth of the sulcus. The incision traverses the hairless skin in the retroauricular region at a point sufficiently high to be invisible if the patient were to have short hair or be wearing hair in ponytail. The incision then extends along the hairline for a short distance (1.5 cm) and passes back into the occipital scalp in the form of an “S” or an inverted “V.” When the neck skin is redraped, it is difficult to completely avoid a step-off in the hairline. If the incision extends too far down the hairline before passing into the scalp, this step-off, however small, is more noticeable. Hence the recommendation to limit the hairline portion to 1.5 cm.

### Undermining

Once the incisions are made, undermining is performed. The extent of undermining depends on the degree of aging changes,

the area where these changes exist, the surgeon’s instinct about the health and vascularity of the tissues, and the manipulation planned for the deeper tissues. The various options for deep-tissue manipulation are summarized below. Depending on the extent of undermining performed, a fiberoptic retractor may provide useful visualization. Many experienced surgeons undermine using a “blind” technique, gauging the depth of the dissection by feel and by watching the skin as the knife or scissors move beneath it. **I prefer—and strongly recommend—that dissection be performed under direct vision.** The tissues involved are thin and it only takes a minor slip of the scissor tip to cut a branch of the facial nerve and result in permanent disability for the patient. Some surgeons also find that countertraction applied by an assistant facilitates the dissection. The neophyte should be aware that the stronger the countertraction, the thinner the skin flap that is usually dissected. Although one wants to avoid dissection that is too deep, a flap that is too thin is also not desirable.

### Redraping

The undermined skin flap is redraped in a cephaloposterior direction. The transverse incision is made below the sideburn. The superior flap, with the sideburn on it, is fixed at the level of the ear–cheek junction—and no higher! The cheek skin is redraped along a line from the chin to the sideburn, overlapping the previously fixed flap. A triangle of hairless, excess cheek skin is excised and the cheek is fixed under some tension with a single suture at the top of the ear, in such a way that there is no dog-ear at the anterior end of the transverse incision. The neck skin is redraped more horizontally, parallel to the neck creases. A second suture is placed under some tension at the apex of the retroauricular incision. Care is taken not to redrape the transverse neck creases up on to the face. This creates another bizarre “facelift look.” Once these two tension-bearing sutures have been placed, the flap is incised so that the ear can barely be withdrawn from beneath the flap. The cheek flap is tucked up under the earlobe, leaving no possibility that the scar will be visible. The excess skin in front of and behind the ear is trimmed with extreme conservatism so that there is absolutely no tension on the closure. There should be almost no need for sutures because the coaptation of the skin edges is so precise. If a retrotragal incision is used, the tragal flap is cut so that it is redundant in all directions. The skin over the tragus tends to contract and, if there is not sufficient excess, will pull the tragus forward, opening the view to the external auditory canal. A closed suction drain is left in the neck in the most dependent portion of the incision.

Regardless of the technique chosen for facelifting, the incisions and the final redraping are critical. If the incisions are performed properly, the redraping is appropriate, and the patient experiences uncomplicated wound healing, it is frequently difficult for the surgeon or the hairdresser to find the scars.

## SMAS Dissections

### Traditional SMAS Dissection

SMAS dissections vary in extent. The “traditional” SMAS dissection involves a transverse incision in the SMAS at a level just below the zygomatic arch and an intersecting preauricular SMAS incision that extends over the angle of the mandible and along the anterior border of the sternomastoid muscle. The SMAS is elevated off the parotid fascia, a separate anatomic structure, in continuity with the platysma muscle in the neck. The end point of the dissection is just beyond the anterior border of the parotid gland. The SMAS over the parotid gland is relatively immobile, compared to the SMAS beyond the gland.

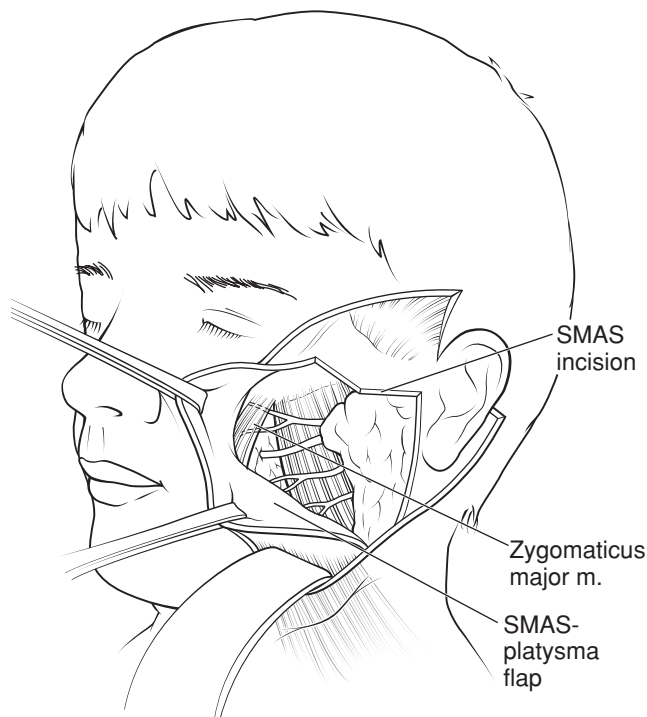
If dissection is not performed beyond the gland, insufficient release occurs, and tension on the SMAS is less efficiently transmitted to the jowls and neck. The SMAS-platysma flap is rotated in a cephaloposterior direction, trimmed, and sutured to the immobile SMAS along the original incision lines. The platysma portion of the flap is sutured to the tissues over the mastoid, increasing the definition of the mandibular angle.

The traditional SMAS dissection is effective for minimizing the jowls and highlighting the mandibular angle.

### Extended SMAS Dissection

The extended SMAS dissection differs in two ways from the traditional SMAS dissection: the level of the transverse incision and the anterior extent of the dissection. The transverse incision is made above the zygomatic arch. Although concern has been expressed about the safety of this maneuver, it can be performed safely on a consistent basis with appropriate training. The same intersecting incision is made in the preauricular region and along the sternocleidomastoid muscle. The flap is elevated well beyond the anterior end of the parotid. The zygomaticus major is visualized. Dissection continues over the superficial surface of this muscle to avoid its denervation (Fig. 49.4). The large SMAS-platysma flap is rotated in a cephaloposterior direction, trimmed, and sutured along the original incision lines. The platysma is sutured to the mastoid periosteum.

The extended SMAS has the advantage of providing malar augmentation as well as an effect on the jowls and neck. It is my opinion, after performing this technique for many years, that there is a trade-off: the benefit of the high dissection is offset somewhat by a less-efficient effect on the jowls. The greater distance between the point of fixation and the jowls in the extended technique accounts for this difference.



**FIGURE 49.4.** Extended SMAS dissection. The SMAS flap is elevated, revealing the buccal branches of the facial nerve lying on the surface of the masseter muscle. The dissection passes over the superficial surface of the zygomaticus major, preserving its innervation.

## SMASectomy and SMAS Plication

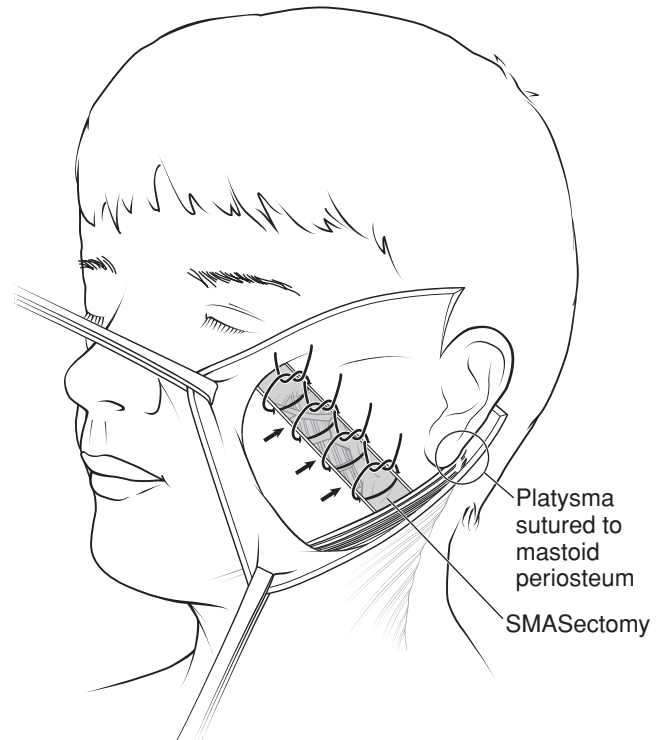
### SMASectomy

Baker described the lateral SMASectomy procedure (8), and some variation of this technique is probably the most frequently performed facelift technique in the United States today. A strip of SMAS is excised on an oblique line between the angle of the mandible and lateral canthus (Fig. 49.5). The mobile SMAS is sutured to the immobile SMAS, accomplishing all the benefits of both the traditional and extended SMAS procedures. The platysma is sutured to the mastoid in a manner identical to a formal SMAS dissection.

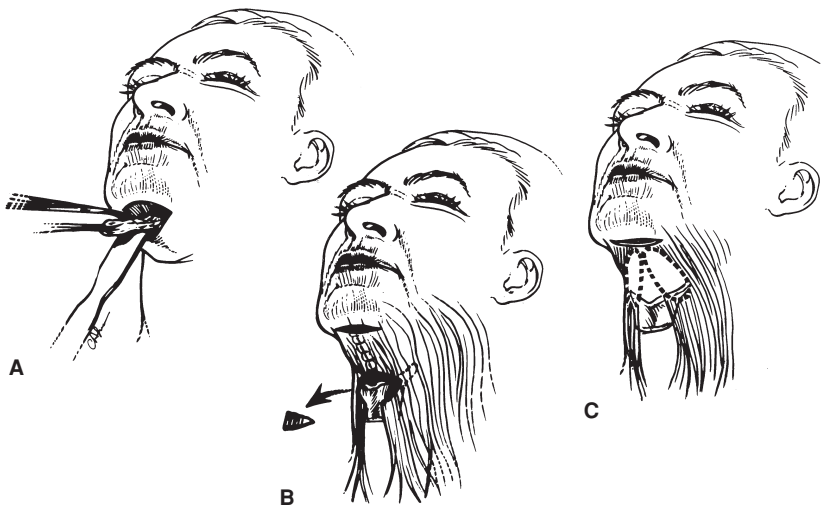
### SMAS Plication

In thin patients, the SMAS can be plicated along the same line, without removing any tissue. Although it may be necessary to remove a small amount of redundant SMAS over the angle of the mandible, the rest of the tissue is preserved. With the current trend of fat preservation, this is an appealing alternative. In heavier faces, the SMASectomy alternative is preferable.

The technique has enormous advantages. It is simple in design, can be modified to suit different facial shapes, and is less time-consuming than other techniques. It provides the malar augmentation of the extended SMAS with the more efficient effect on the jowls of the traditional SMAS procedure. It has the theoretical additional benefit that the SMAS is not undermined and thus not subject to the devascularization and atrophy that



**FIGURE 49.5.** SMASectomy. The oblique strip of SMAS to be excised is shown, extending from the angle of the mandible to the lateral canthal region. The platysma muscle in the neck is sutured to the mastoid periosteum. The mobile SMAS anterior to the SMASectomy is advanced to the immobile SMAS. This illustration shows the SMAS being advanced in an oblique cephaloposterior direction. In fact, the oblique SMASectomy defect can be closed in a vertical fashion (imagine the *black arrows* pointing vertically). The more vertical the closure, the greater the effect on the neck.



**FIGURE 49.6.** Treatment of medial platysma and platysma bands. Alternatives include (A) defatting of the anterior platysma without muscle modification; (B) midline platysmaplasty with wedge excision; and (C) resection of platysma bands without midline approximation. If a submental incision is elected, option (B) is usually the best alternative.

can occur when SMAS flaps are elevated. The disadvantage is that injury to buccal branches of the facial nerve can occur if sutures are placed too deeply.

### Deep Plane or Composite Rhytidectomy

Hamra described the deep plane facelift that he modified to its current iteration, the composite rhytidectomy (9). This brief description does not do the technique justice, but does outline the key points. The SMAS and skin are dissected together as a single flap, rather than independently, as in the techniques described above. The benefit of the procedure is that theoretically the flap is better vascularized and less likely to slough. The technique, as Hamra performs it, includes a superomedial elevation of the malar tissues and orbicularis oculi muscle and a brow lift with a similar superomedial vector. The disadvantage of the technique is the magnitude of the procedure and the prolonged recovery period.

It is my opinion, *never* having performed this procedure myself, that the benefits of the procedure do not justify the invasiveness, risk, and prolonged recovery associated with the procedure.

### Rejuvenation of the Neck

The procedures outlined above have a beneficial effect on the neck. In some patients, however, additional procedures are required, in combination with the above, to provide better definition to the neck. Some of these procedures are controversial.

#### Submental Dissection and Platysmaplasty

The SMASectomy procedure, with its efficient elevation of the jowl and submental tissues, has decreased the need for submental incisions and open-neck procedures. As mentioned above, the closure of the SMAS (or the plication of the SMAS if no tissue is removed) is performed at a shorter distance from the jowls and submental region, and has a profound effect on those areas. There are, however, patients with enough redundant skin, excess fat, and redundant platysma who still require a formal submental dissection.

In these patients, an incision is made just caudal to the submental crease. Subcutaneous undermining is performed. A judgment is made about defatting of the platysma muscle, as mentioned below. An independent decision is made regarding removal of subplatysmal fat. The medial borders of the

platysma muscle are plicated in the midline using buried interrupted sutures (Fig. 49.6). Compulsive attention to both hemostasis and perioperative blood pressure control is essential to prevent a hematoma when this larger dead space is created.

#### Corset Platysmaplasty

Feldman described the corset platysmaplasty. The medial borders of the platysma are plicated with a continuous monofilament suture that is run up and down the midline of the neck until the desired contour has been achieved. No manipulation of the lateral border of the platysma is performed.

I have had better experience with buried, interrupted sutures, which cause less bunching of the muscle. I also prefer to combine the midline platysmaplasty with lateral tightening of the platysma as described above under “SMAS Techniques” and “SMASectomy.”

#### Defatting of the Neck

A guiding principle is preservation of facial fat. This principle also applies to the neck but less so. Many patients benefit aesthetically from cervical defatting. The surgeon is meticulous about avoiding overdefatting because unsightly adhesions between the skin and platysma can occur. The same applies to removal of subplatysmal fat. Overskeletonization of the neck is one stigmata of an amateurish facelift.

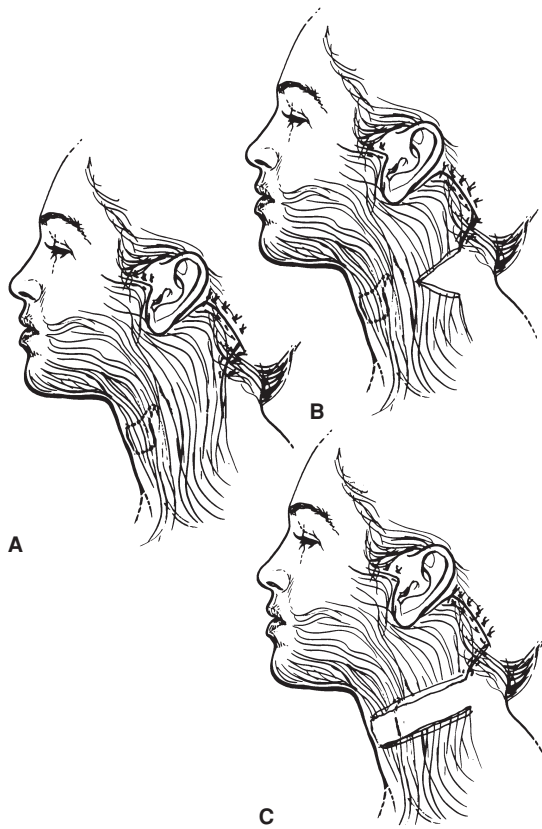
#### Submandibular Glands

The presence of large and/or protic submandibular glands prevents the creation of a clean neck after facelifting. The question of whether excision of the glands is worth the risk of bleeding and nerve injury has not been answered. Sullivan reports an acceptably low complication rate for submandibular gland resection associated with facelifting.

I have not had a complication from submandibular gland resection accompanying a facelift, but no longer believe that the benefits are worth the additional time required or the risk of bleeding and nerve injury.

#### Digastric Muscle Resection

Connell recommends shaving of the anterior belly of the digastric muscles to further define the cervicomental angle. I believe this creates an excessively sculpted, overdone look in many necks and is best avoided.



**FIGURE 49.7.** Lateral platysma modification. Alternatives include (A) advancement of lateral platysma parallel to mandibular border with suture fixation to the mastoid periosteum; (B) partial transection of lateral platysma with similar fixation; and (C) full-width transection of platysma with similar suture fixation. Most SMAS flap and SMAS-ectomy/SMAS plication procedures include tightening of the lateral platysma. The most common alternative is (A). Alternative (B) may provide additional contouring to the mandibular angle in patients who require increased definition. Alternative (C) is the single most powerful technique to increase neck definition, but is associated with a higher incidence of neck irregularities, adhesions between the skin and muscle, and an overcorrected appearance in some patients.

### Full-width Platysma Transection

The single most powerful way to create a well-defined neck is to perform full-width transection of the platysma muscle across the neck (Fig. 49.7C). The muscle is divided under direct vision at least 6 cm below the inferior border of the mandible.

I only employ this technique in the most difficult necks, because irregularities and an overoperated look can be created and there is additional risk of hematoma and prolonged induration in the neck.

### Short-Scar Technique

Baker described the “short-scar” procedure, in which all the elements of the subcutaneous dissection with SMASectomy and lateral platysma tightening are performed, but the skin incision is limited to the preauricular portion. It is useful in younger patients with minimal excess neck skin. The incision is not extended beyond the earlobe, thereby avoiding the postauricular incision and the extension into the hairline. The technique relies on vertical redraping of the skin. Bunching of skin behind the earlobe often occurs but improves with time. Care is taken, however, to distribute the bunching as much as possible because

patients will complain about it, even if it eventually improves. There is no question that the absence of the retroauricular incision is an advantage. While the retroauricular incision in most patients having traditional facelift heals well and is sometimes virtually invisible, there are patients in whom this is *not* the case and the scar is visible, slightly hypertrophic, and, despite the surgeon’s best efforts, there is a slight step-off in the occipital hairline.

### MACS Lift

Tonnard described the minimal access cranial suspension (MACS) lift, which employs purse-string sutures in the SMAS structures and malar fat pad with vertical suspension (10). The vertical nature of the lift requires an incision along the anterior sideburn and anterior temporal hairline. The procedure can be performed in combination with midline platysmaplasty to improve the results in the neck. Excess skin may appear below the earlobe, which may require posterior cervicoplasty to correct.

### Subperiosteal Facelift

Originally described by Tessier, Heinrichs has reported a large series of subperiosteal facelifts (11). The procedure is designed to rejuvenate the upper and middle thirds of the face. Subperiosteal undermining is performed through the following incisions in various combinations, depending on the surgeon: coronal incision or endobrow approach, subiliary incision, or an upper buccal sulcus incision. Hester has described a subperiosteal midface lift using endoscopic assistance through the lateral aspect of a lower-eyelid incision (12).

I am not impressed with the effectiveness or the longevity of subperiosteal lifts, but surgeons who have extensive experience with the technique probably have better results. Postoperative swelling can be profound after subperiosteal undermining. The author believes that the closer one is to that which is being lifted (i.e., the skin), the more effective the lift and considers subcutaneous undermining the gold standard.

### Secondary Facelifting

The goals of secondary facelifting are to (a) relift the face and neck, (b) remove the primary facelift scars, and (c) preserve maximum temporal and sideburn hair. Dissection is usually easier than the primary facelift. Intraoperative bleeding and postoperative hematomas are also less frequent. The amount of skin excised at a secondary lift is much less than at the primary procedure. For this reason pre-excision of skin is never performed for a secondary facelift. The risk of nerve injury may be slightly higher in secondary facelifts, however. The first procedure may have distorted the anatomy and the tissues may be abnormally thin.

### Facelifting in Men

The shorter hairstyles of men are less forgiving than the longer hairstyles of women. Male faces tend to be larger and dissection is more time-consuming. Modified incisions have been described for men, but I use the same incision in patients of both sexes. Some men may have a tremendous amount of excess skin in the neck. When this is redraped into the retroauricular area, care is required to avoid a large step-off in the hairline. The previously reported higher incidence of hematomas in men than in women seems to be largely related to blood pressure.

When blood pressure is controlled, the hematoma rates are very similar.

---

### Barbed Sutures

---

In an effort to make facelifting quicker and less invasive, several authors describe the use of barbed sutures in facelifting. The longevity of the result does not compare favorably with traditional methods. At the present time, the sutures are made of polypropylene and are permanent. Concerns have been raised regarding the safety of permanent barbed sutures in the subcutaneous position. Long-term data are not yet available.

---

## POSTOPERATIVE CARE

---

Although in most cases the patients do not require hospitalization, ideally they do have an experienced nurse to monitor them closely. Patients are instructed to rest with the head elevated for the first several postoperative days. Blood pressure is monitored and kept under strict control for the first 24 hours. The drains are usually removed on the first postoperative morning and showering and shampooing are encouraged at that point. Pain medication is usually required, especially at night, for several days. Oral antibiotics are generally prescribed, although there is no evidence that they are beneficial. Studies show that steroids are of no benefit in reducing swelling. Sutures are removed progressively beginning on the fourth postoperative day. All the sutures are usually gone by the eighth postoperative day.

Swelling and bruising are variable. Depending on the ancillary procedures performed, patients look reasonably acceptable after 1 week, good with makeup after 2 weeks, and able to attend social functions after 3 weeks. An occasional patient will have prolonged bruising that may limit activity for a longer period of time.

---

## PATIENT SAFETY AND COMPLICATIONS

---

Despite constant attention to detail, complications do occur. The most common problems and methods to prevent and to treat such complications are summarized in the following sections (13).

---

### Hematoma

---

Hematomas are by far the most common complication after facelifting and vary from large collections of blood that threaten the survival of the skin flaps (and even compromise the airway) to small collections that are evident only when facial edema has subsided. Most major hematomas occur during the first 10 to 12 hours postoperatively.

The most common presentation of a hematoma is an apprehensive, restless patient experiencing pain insolated to one side of the face or neck. Because localized and worsening pain is unusual following an uncomplicated facelift, it must be regarded as a sign of hematoma until proven otherwise. Rather than provide analgesics for pain relief, the surgeon or nurse removes the dressing immediately to permit examination. In addition to causing skin flap ischemia, a large expanding hematoma under tight skin flaps has the potential to cause respiratory compromise.

The treatment for a hematoma of any degree is evacuation. If the collection is rapidly enlarging or if the flaps appear compromised, then sutures may be removed at the bedside for im-

mediate relief of some of the pressure. Depending on the extent of the bleeding, the emotional state of the patient, and the availability of an operating room, the hematoma is either evacuated at the bedside or in the operating room. The important thing is to get the blood out. If formally explored, a specific bleeding point will rarely be found. If evacuated at the bedside, the patient must be sedated and the blood pressure reduced. Catheters are inserted and the hematoma is evacuated. The region is irrigated with saline until clear, and then with a 0.25% solution of lidocaine containing epinephrine 1:400,000. Gentle pressure is placed on the flap for 20 minutes. If this method does not result in complete removal of the hematomas, then the facelift wound is formally explored under adequate anesthesia to permit visualization and precise control of any bleeding.

The reported incidence of hematomas requiring evacuation ranges from 0.9% to 8.0%, but is approximately 3% to 4% when all studies are combined. Because most patients in the reported studies were women, this 3% to 4% range represents the incidence in female patients. Early studies demonstrated a hematoma rate in men of 7% to 9%, or twice that of women. More recent studies suggest that this difference between the two sexes is at least partly a consequence of blood pressure. When blood pressure in male patients is compulsively controlled, the incidence falls precipitously, approaching that of women.

As mentioned in the "Preoperative Preparation" and "Anesthesia" sections, blood pressure control is the single most important preventative measure. Ranking next in importance is the avoidance of medications that interfere with clotting or coagulation. Finally, every attempt is made to prevent vomiting, coughing, anxiety, or pain.

Small hematomas of 2 to 20 mL that are not apparent until edema begins to subside are a totally different entity and occur in 10% to 15% of patients. Initially, an area of firmness is palpable followed by ecchymosis in the overlying skin. Although somewhat controversial, it is my opinion that every effort should be made to evacuate even the small hematomas. A syringe and large-bore needle are used. Aspiration is repeated every few days until the collection is completely gone or no further liquid can be withdrawn. Repeated aspiration attempts are especially important in the neck where larger collections can be hiding. If the blood is not evacuated, the patient may develop a firm, woody, wrinkled mass that takes months to resolve, and in some cases leaves permanent changes in the skin. Compulsive attention to hemostasis, blood pressure control, drain placement, and postoperative management is required to obtain the best possible results in the neck. Rest-on foam applied to neck as the original dressing may also be of benefit.

Neck hematomas are more common when submental dissections are included in the facelift procedure. This fact, combined with the beneficial effect on the neck that accompanies the SMASectomy/SMAS plication techniques, has led to a smaller percentage of patients having submental incisions and midline platysmaplasties. The cost-to-benefit analysis between opening the neck to improve neck definition and avoiding submental dissections to prevent complications is a judgment that must be made for each patient, with the knowledge that neither choice may be perfect.

Triamcinolone (Kenalog) injections to small hematomas and areas of firmness are discouraged. They probably offer no benefit over watchful waiting and hematoma aspiration, and can result in subcutaneous atrophy and a depression when the hematoma resolves.

---

### Skin Slough

---

Luckily for the patient and the surgeon, the most common location for skin slough is in the retroauricular area where the scarring is less visible. The bad news is that full-thickness

skin loss will inevitably result in less-favorable scarring, which can be distressing to the patient and prevent the patient from wearing certain hairstyles. If the skin necrosis occurs in the preauricular area, it is a devastating complication.

The incidence of skin necrosis is 1% to 3%. The most likely causes of skin slough are (a) unrecognized hematomas, (b) a skin flap that is too thin or is damaged during flap dissection or burned with electrocautery, (c) excessive tension on wound closure, (d) cigarette smoking, and, possibly, (e) dehydration. There is no question that smoking increases the risk of skin slough. It is my impression that patients who are well hydrated tend to heal faster with a lower incidence of skin slough.

If the skin appears compromised at any point in the post-operative period, antibiotic ointment or silver sulfadiazine (Silvadene) cream is applied. The surgeon would much rather apply ointment to an area that turns out to be a partial-thickness injury than miss an area that is dying where some of the damage could be limited by aggressive wound care.

The treatment of skin slough is not surgical; it is conservative wound care. Areas of necrosis will contract dramatically and eventually epithelialize. The final scar, although permanent, is almost always better than would be anticipated from the initial wound appearance. If a secondary facelift is performed in an attempt to remove the scars, minimal excess skin will be present, and it may not be possible to remove scar that is more than 1 cm from the previous incision.

---

### Nerve Injury

---

Injury to a branch of the facial nerve (cranial nerve [CN] VII) is the complication most dreaded by patients. Motor nerve injury occurs in 0.9% of patients who receive subcutaneous undermining only, but is more common with dissection of the SMAS, either as an independent layer or in a composite rhytidectomy. Many nerve injuries are temporary, presumably the result of traction or cautery. A nerve that has been transected will not recover function. If the surgeon is aware that a branch has been cut, then immediate intraoperative microsurgical repair is mandated. It is more likely, however, that nerve injury is not recognized during surgery, and the surgeon and patient are placed in the difficult position of waiting for return of function. Injuries to buccal branches tend to improve more than those in the frontal and marginal mandibular territories, presumably because of greater degrees of connections between branches in those areas.

Transient numbness of the cheeks and neck skin is a result of interruption of the small sensory branches during skin undermining and is unavoidable. Sensibility always recovers although it may take months to do so. Injury to the great

auricular nerve is another matter. It is a large sensory nerve, as described under "Facelift Anatomy," and transection will result in permanent numbness of half of the ear and, in some cases, a painful neuroma. The nerve is quite superficial on the surface of the sternomastoid muscle, especially in thin patients, and is easily transected. If such a transection occurs, the nerve should be approximated with appropriate microsurgical suture.

---

### Hypertrophic Scarring

---

Hypertrophic scarring is most often attributable to excessive tension on the incision closure. Some patients, however, develop hypertrophic scars despite the best efforts of the surgeon. As with skin slough, this usually involves the retroauricular area, which is less visible, but can occur in the preauricular area where it is a bad complication. Small volumes of dilute triamcinolone are injected into the scars (not the adjacent normal tissue), sometimes more than once, and this usually improves the appearance of the scar significantly. An occasional patient will get true keloids of the facelift incisions, which are difficult to treat. Scar revision with immediate treatment with radiation is the best option in these difficult situations.

---

### References

---

1. Rees JD, Liverett DM, Guy CL. The effect of cigarette smoking on skin-flap survival in the face-lift patient. *Plast Reconstr Surg.* 1984;73:911.
2. Mitz V, Peyronie M. The superficial musculoaponeurotic system (SMAS) in the parotid and cheek area. *Plast Reconstr Surg.* 1976;58:80.
3. Gosain A, Yousif NJ, Madiedo G, et al. Surgical anatomy of the SMAS: A reinvestigation. *Plast Reconstr Surg.* 1993;92:1254.
4. Stuzin J, Wagstrom L, Kawamoto HK, et al. Anatomy of the frontal branch of the facial nerve: The significance of the temporal fat pad. *Plast Reconstr Surg.* 1989;83:265.
5. Furnas D. The retaining ligaments of the cheek. *Plast Reconstr Surg.* 1989;83:11.
6. Vistnes LM, Souther SG. The anatomic basis for common cosmetic anterior neck deformities. *Ann Plast Surg.* 1979;2:381.
7. McKinney P, Katrana DJ. Prevention of injury to the great auricular nerve during rhytidectomy. *Plast Reconstr Surg.* 1980;66:675.
8. Baker DC. Lateral SMAsectomy. *Plast Reconstr Surg.* 1997;100(2):509.
9. Hamra ST. Composite rhytidectomy. *Plast Reconstr Surg.* 1992;90:1.
10. Tonnard PL, Verpaele A, Gaia S. Optimizing results from minimal access cranial suspension lifting (MACS-lift). *Aesth Plast Surg.* 2005;29(4):213.
11. Heinrichs HL, Kaidi AA. Subperiosteal facelift: A 200-case, 4-year review. *Plast Reconstr Surg.* 1998;102(3):843.
12. Hester TR, Codner MA, McCord CD, et al. Evolution of technique of the direct transblepharoplasty approach for the correction of lower lid and mid-facial aging: Maximizing results and minimizing complications in a 5-year experience. *Plast Reconstr Surg.* 2000;105(1):393.
13. Baker DC. Complications of cervicofacial rhytidectomy. *Clin Plast Surg.* 1983;10:543.